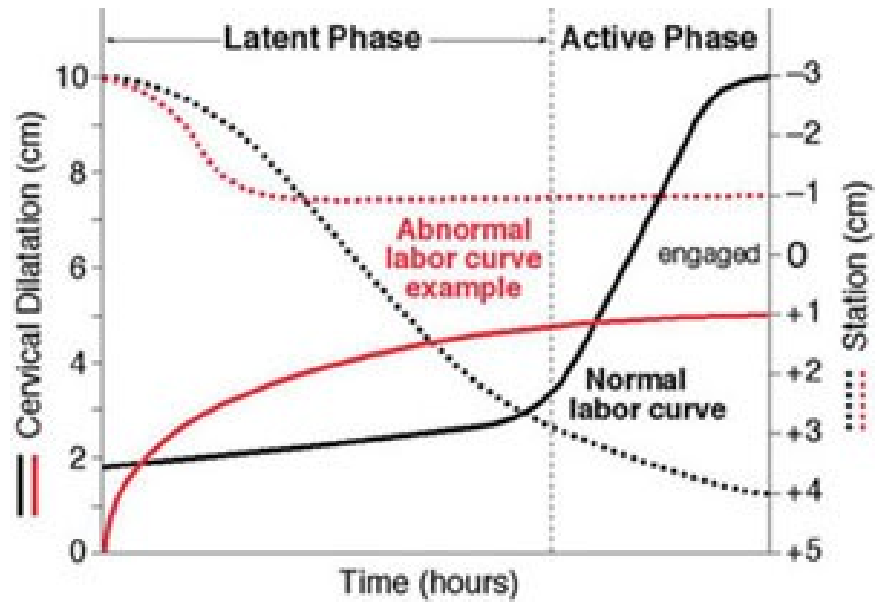


Friedman curve



Abnormal labor progress in red.
Cervical dilatation solid line and station dotted.